

PACIFIC JOURNAL OF MEDICAL SCIENCES

{Formerly: Medical Sciences Bulletin}

ISSN: 2072 – 1625



Pac. J. Med. Sci. (PJMS)

www.pacjmedsci.com. Email: pacjmedsci@gmail.com.

CASE REPORT

TRAUMA INDUCED CALCIFICATION - AN ENIGMA

***Vijayendranath Nayak, Raghavendra Kini, Prasanna Kumar Rao, Ashwini Baliga,
Gowri P Bhandarkar and Roopashri Rajesh Kashyap**

Department of Oral Medicine and Radiology, A.J .Institute of Dental Sciences, Kuntikana, Mangaluru, Karnataka, India.

*Corresponding author: drnayakomr@gmail.com

Running title: Calcified canal– A Case series

CASE REPORT**TRAUMA INDUCED CALCIFICATION - AN ENIGMA**

***Vijayendranath Nayak, Raghavendra Kini, Prasanna Kumar Rao, Ashwini Baliga,
Gowri P Bhandarkar and Roopashri Rajesh Kashyap**

Department of Oral Medicine and Radiology, A.J .Institute of Dental Sciences, Kuntikana, Mangaluru, Karnataka, India.

*Corresponding author: drnayakomr@gmail.com

Running title: Calcified canal– A Case series

ABSTRACT:

Pulp chamber is considered as a very important and integral part of the tooth. Pulp chamber undergoes different types of morphological and pathological alterations. Calcified canals are one amongst other pathological alterations. Calcified root canals have been a challenge to the diagnostician and the dental physician before diagnosis and after diagnosis respectively. It is considered that the impact of an irritant to the tooth, like trauma, caries, infection and age changes can precipitate calcification. Calcification makes a dentist to negotiate with his treatment planning and at times it can be a surprise element.

Keywords: Pulpal calcification, Trauma, Ellis Classification, Pulpal necrosis

INTRODUCTION:

Calcification is considered to be the pulpal sequelae to trauma and aging phenomenon in an individual [1]. The exact mechanism of pulp canal calcification is unknown. Theoretically it may be because the sympathetic/parasympathetic blood flow to odontoblasts is altered, resulting in uncontrolled reparative dentin [1]. Another theory is that hemorrhage and blood clot formation in the pulp after injury is a nidus for calcification if pulp remains vital [2]. Microscopically, this calcific metamorphosis is characterized by multifocal, dystrophic

calcifications usually, composed of ill-defined secondary dentin [3,4]. Pulpal calcification remains to be a challenging task for dentist in treating and achieving a desired outcome. Herein we report two case of trauma induced pulpal calcifications.

CASE REPORT 1:

A 22 year old medically fit male patient came to the department of oral medicine and radiology with a chief complaint of broken teeth in upper front tooth region since 5 years associated with a fall from a two wheeler. Patient gave a history of root canal treatment 5 months ago, which he

had to discontinue due to personal reasons. He gave no history of deleterious habits and was moderately built and nourished. No significant extraoral findings were noted. Intraoral examination revealed loss of crown structure involving enamel and dentine in relation to right and left maxillary right central incisor.

Discoloration of the crown was seen in left maxillary central incisor with an access opening seen on the lingual aspect. On palpation and percussion no tenderness was evident.

A provisional diagnosis of Ellis Class IV fracture in relation to left maxillary central incisors and Ellis Class II fracture in relation to right maxillary central incisors was given. Electric pulp testing was conducted with negative response. Intraoral periapical radiograph was advised which revealed wide pulp chamber and canal, with open apex in the left maxillary central incisor with root resorption at the apex. Maxillary right central incisor revealed calcification of the root canal (Figure 1). A final diagnosis of Ellis Class IV fracture with root resorption in relation to left maxillary

central incisor and Trauma induced pulpal calcification was given in relation to Maxillary right central incisor. Patient was referred to the department of endodontics for endodontic therapy.

CASE REPORT 2:

A 24 year old female patient came to the department of oral medicine and radiology with a chief complaint of discolored teeth in upper front tooth region since 2 years, with no history of pain; patient gave a history of fall 4 years ago. Past medical and dental history was non contributory. Intraoral examination revealed yellowish discoloration of coronal aspect of right maxillary central incisors. No tenderness elicited on palpation and percussion.

A provisional diagnosis of Ellis Class IV fracture was given. Electric pulp testing gave a negative response. Intraoral periapical radiograph revealed calcification of coronal and radicular part of the pulp canal, suggestive of trauma induced calcification (Figure 2). Patient was referred to speciality of endodontics and prosthodontic evaluation.

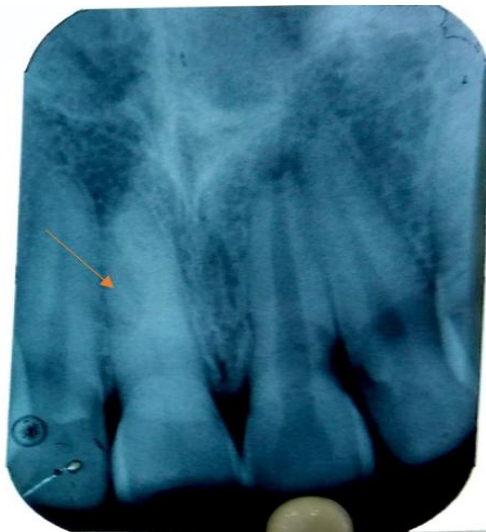


Figure 1: Pulpal calcification seen in Maxillary right central incisor. widening of pulp chamber and canal along with root resorption of maxillary left central incisors

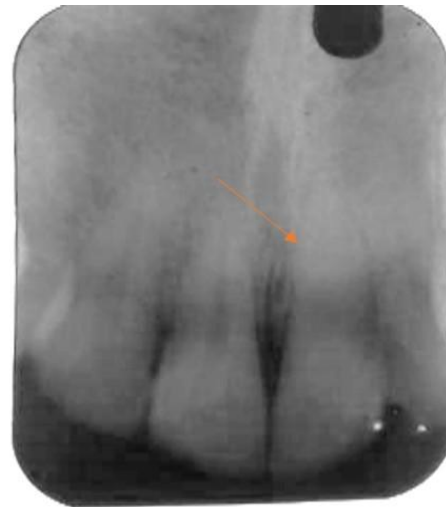


Figure 2: Pulpal calcification seen in Maxillary right central incisor

DISCUSSION:

Dental pulp calcification presents as masses of calcified tissue present on the level of the pulp chamber and roots of the teeth [5]. Dental pulp calcification occurs in all age groups with an increase in frequency in older age groups and in those teeth where there is an insult to pulp [6]. The formation of pulp stones has also been associated with long-standing irritants such as caries, deep fillings, and chronic inflammation. Despite a number of microscopic and histochemical studies, the exact cause of such pulp calcifications remains largely unknown [7].

The two chief morphologic forms of pulp calcifications are discrete pulp stones (pulp nodules, denticles) and diffuse calcifications. Pulp stones are classified as per their structure

into true denticles and false denticles. True denticles are made up of localized masses of calcified tissue that resemble dentin because of their tubular nature. Actually these tubules bear greater resemblance to secondary dentin than to primary dentin, since the tubules are few and irregular. They are considerably more common in pulp chamber than in root canal [8].

False denticles are composed of localized masses of calcified material and unlike true denticles do not exhibit tubules. Instead the nodules appear to be made up of concentric lamellae or layers deposited around a central nidus. The exact nature of this nidus is unknown, although Johnson and Bevelander believe it is composed of cells, as yet unidentified, around which is laid down a layer of reticular fibers that subsequently calcify [8].

Pulp calcifications have been noted in patients with systemic or genetic disease such as dentin dysplasia, dentinogenesis imperfecta and in certain diseases such as Vander Woude syndrome [9].

The presence of calcifications does not affect the threshold of electric pulp testing, as was obtained in both the reported cases. Completely calcified canals can be untreated, but should be kept on constant observation, and if discoloration of the coronal aspect of the teeth is noted, prosthetic rehabilitation becomes mandatory [10]. In case of partially calcified canals management includes, orifice recognition, biomechanical preparation and use of chelating agents like EDTA can be considered [11,12].

CONCLUSION:

Knowing the anatomy of the teeth and its developmental and pathological changes plays a major role in giving beneficial treatment to the patient. Evaluation of such pathologies and age changes are of utmost importance so that more and more research can be carried out in giving clarity about any such kind of phenomenon.

REFERENCES:

1. Akpata ES. Traumatized anterior teeth in Lagos school children. *J Niger Med Assoc.* 1969; 6:40–5.
2. Keijoluuko, OaiviKettunen, IngeFristad& Ellen berggreen. Structure & function of

- dentin-pulp complex. Cohen's pathway of the pulp. 10th edition; pp. 452-503
3. Eversole L.R.: *Clinical Outline of Oral Pathology: Diagnosis and Treatment.* Lea and Febiger, Philadelphia 1978, 273-4.
4. Bevelander G, Johnson PL. Histogenesis and histochemistry of pulpal calcification. *J dent res.* 1956;35(5):714-22.
5. Deva V, Mogoantă L, Manolea H, Pancă OA, Vătu M, Vătăman M. Radiological and microscopic aspects of the denticles. *Rom J MorpholEmbryol.* 2006; 47:263–8.
6. Sundell JR, Stanley HR, White CL. The relationship of coronal pulp stone formation to experimental operative procedures. *Oral Surg Oral Med Oral Pathol.* 1968; 25:579–89.
7. Goga R, Chandler NP, Oginni AO. Pulp stones: A review. *Int Endod J.* 2008; 41:457–68.
8. Shafer, Hine, Levy. *Shafer's Textbook of Oral Pathology.* 6th edition; pp.578-9.
9. Kantaputra PN, Sumitsawan Y, Schutte BC, Tochraeontanaphol C. Vander Woude syndrome with sensorineural hearing loss large craniofacial sinuses, dental pulp stones, and minor limb anomalies: Report of four generations Thai family. *Am J Med Genet.* 2002;108:275-80.
10. Moody AB, Browne RM, Robinson PP. A comparison of monopolar and bipolar electrical stimuli and thermal stimuli in determining the vitality of human teeth. *Arch Oral Biol* 1989;34:701-5.
11. Weine FS. *Endodontic Therapy,* 5th edition, St Louis: Mosby-Yearbook; 1996:230-45.
12. Lovdahl PE, Gutmann JL. Problems in locating and negotiating fine and calcified canals. In: Gutmann JL, Dumsha TC, Lovdahl PE, Hovland EJ, editors. *Problem Solving in Endodontics. Prevention, Identification and Management.* 3rd ed. St. Louis: Mosby; 1997. pp. 69–89.